

# Most prevalent oral manifestations in patients infected by the HIV virus and the importance of dentists in early diagnosis

Jennifer Letícia Moura da Silva<sup>1</sup>, Rafaela de Souza Sampaio<sup>1</sup>, Lívia Coutinho Varejão<sup>1</sup>, Gerson de Oliveira Paiva Neto<sup>1</sup>, Rebeca Luzia Solarte Barbosa<sup>2</sup>, Mário Jorge Souza Ferreira Filho<sup>2</sup>

<sup>1</sup>Centro Universitário FAMETRO

<sup>2</sup>Centro Universitário do Norte - UNINORTE

Received: 03 Oct 2021,

Received in revised form: 25 Oct 2021,

Accepted: 03 Nov 2021,

Available online: 09 Nov 2021

©2021 The Author(s). Published by AI  
Publication. This is an open access article  
under the CC BY license

(<https://creativecommons.org/licenses/by/4.0/>).

**Keywords**—Oral manifestations, HIV,  
dentists, early diagnosis.

**Abstract**—The Human Immunodeficiency Virus (HIV) promotes chronic infection of TCD4+ lymphocytes, resulting in depression of the immune system and making the body susceptible to the development of opportunistic infections, yet it can evolve into Acquired Immunodeficiency Syndrome (AIDS). The oral cavity of the HIV-infected patient is constantly affected by pathologies and neoplasms of different origins, which makes the dentist essential for the early diagnosis of these lesions, treatment and, consequently, for the promotion of the quality of life of this individual. The present work aims to portray the most prevalent oral manifestations in HIV-infected patients and emphasize the importance of the dentist in early diagnosis. After reviewing the literature, it is concluded that the most prevalent manifestations are: candidiasis (pseudomembranous, erythematous, angular and hyperplastic cheilitis), oral hairy leukoplakia, Kaposi's sarcoma, non-Hodgkin lymphoma and periodontal disease (linear gingival erythema, periodontitis necrotizing ulcerative and necrotizing ulcerative gingivitis).

## I. INTRODUCTION

The first cases of acquired immunodeficiency syndrome (AIDS) were reported by the Centers for Diseases and Control and Prevention (CDC) in the United States in 1981. The report described Pneumocystis carinii pneumonia and Kaposi's sarcoma in five men previously healthy and from Los Angeles, California, however, it was only listed as the cause of the disease in 1984 (PAULIQUE et al., 2017).

As the number of cases grew, social stigma also took root in society and as a result of the lack of knowledge about the new pathology, the media published news full of prejudice and without scientific evidence that associated the

disease with homosexuals. It is now known that AIDS is caused by the Human Immunodeficiency Virus (HIV), which promotes chronic infection of TDC4+ lymphocytes, resulting in depression of the immune system and making the body vulnerable to the development of various opportunistic infections. (NASCIMENTO et al., 2020).

According to Paulique et al. (2017), the oral cavity of patients with HIV/AIDS is frequently affected by pathologies and neoplasms of different etiologies. In addition, the manifestations of the oral cavity can be one of the first signs of infection, making the dentist an extremely important actor in the early diagnosis of HIV infection.

For Barros et al. (2017), the manifestations of oral lesions or their absence has been an effective marker of the effectiveness of highly active antiretroviral therapy (HAART). Several studies have shown the most common pathologies found in the oral environment of seropositive patients, namely candidiasis in its pseudomembranous, erythematous and angular cheilitis forms, followed by periodontal diseases, hairy leukoplakia (PAULIQUE et al., 2017), Kaposi's sarcoma and non-Hodgkin lymphoma (NEVILLE, 2016).

Given the above, this work aims to portray the main oral manifestations associated with HIV and emphasize the importance of the dentist in the early diagnosis of these lesions.

## II. LITERATURE REVIEW

According to Brito (2011), it is known that HIV was discovered in 1981, in the United States, and the origin of the disease is still unknown. After the first diagnosis, studies found two types of HIV: HIV-1, which is more prevalent, with a high mutation rate and more spread around the world, and HIV-2, which has a lower degree of pathogenicity and transmission compared to HIV-1. The HIV-2 transmission rate is so much lower that it is more restricted in West Africa, in countries like Guinea, Senegal, Cape Verde and Gambia.

HIV is a retrovirus that affects the immune system, which causes AIDS. This virus mainly affects the TCD4+ lymphocytes, which are the body's defense cells. After the virus enters the organism, it has a replicative cycle divided into five stages: (1) fusion, when the virus fuses with the cell molecule; (2) reverse transcription, when there is reverse transcription in the formation of a DNA from an RNA; (3) integration, after the retrotranscription of the proviral DNA double strand, incorporation into the cell nucleus occurs; (4) transcription is the time when proviral DNA is transcribed into viral RNA; (5) translation, is the moment when the immature virus undergoes maturation and budding through the cell membrane (BRITO, 2011).

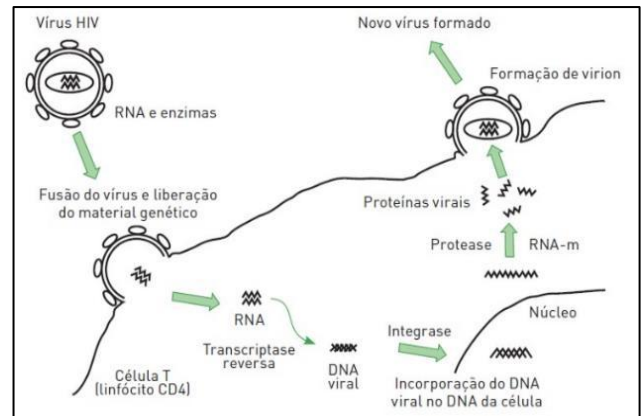


Image1 - Summary life cycle of HIV viral replication Source: BRITO, 2011.

In the view of Dominguez Filho et al. (2021), HIV cannot progress on its own, so it infects any cell that has CD4 as a receptor. Helper T lymphocytes are greatly affected, as are macrophages, monocytes, Langerhans cells, neurons, and glial cells. In addition, the level of CD4+ cells (1,000 to 1,200/mm<sup>3</sup>) drops to less than 200/mm<sup>3</sup> in the later stages of AIDS. Initially, HIV infection may be asymptomatic and may last for about 8 to 10 years. But this asymptomatic period can vary according to external factors stimuli or immune reaction that can accelerate or delay the process. Still, an acute response resembling infectious mononucleosis can occur with the manifestation of generalized lymphadenopathy, headache, diarrhea, sore throat, fever, arthralgia, and myalgia. In the oral cavity, the presence of focal ulcerations and mucosal erythema can be noted. And this acute phase disappears within a few weeks, and the need to investigate the cause may go unnoticed (NEVILLE, 2016). As the virus multiplies and destroys TCD4+ lymphocytes, it depresses the host's immune system, leading to the development of opportunistic infections. This is when the acquired immunodeficiency syndrome (AIDS) occurs. The process from HIV infection to an individual reaching the AIDS stage can take many years. The means of HIV transmission are: unprotected sex, contaminated blood transfusion, accidents with sharp instruments, through mother to child during the perinatal period and breastfeeding (QUARESMA et al., 2019). As described by Neville (2016), oral manifestations can be among the first clinical signs of HIV infection and can also guide its progression to AIDS. Since the signs in the oral cavity are very common, the dentist is the first to find them, becoming responsible for the early diagnosis or diagnostic hypothesis that will refer the patient to the proper treatment.

However, there is still a lot of lack of information and prejudice from some professionals, which leads patients who are already aware of their serological condition to stop seeking dental care. Therefore, it is essential that the dentist is

prepared to identify the oral manifestations of the pathology and treat them properly in order to improve the quality of life of people living with HIV (PLHIV) (NASCIMENTO et al., 2020).

Despite the existence of many studies and prevention campaigns, HIV infection is still an important public health problem. However, the use of Highly Active Antiretroviral Therapy (HAART) increased the life expectancy of PLHIV, enabling the reduction of viral load to undetectable levels and, consequently, the improvement of the effects of immunosuppression, increasing the number of TCD4+ lymphocytes, resulting in a reduction in the appearance of lesions in the oral cavity (ARAÚJO-JÚNIOR et al., 2018). Oral manifestations are one of the first signs of infection by this pathogen and help in the early diagnosis of those who are unaware of their serological condition. Furthermore, the lesions function as a clinical marker of new virus infections, therapeutic failure or disease progression. Among the lesions strongly associated with HIV, the following stand out: candidiasis (erythematous, pseudomembranous, angular and hyperplastic cheilitis), hairy leukoplakia, Kaposi's sarcoma, non-Hodgkin's lymphoma and periodontal disease (linear gingival erythema, necrotizing ulcerative periodontitis and necrotizing ulcerative gingivitis) (NEVILLE, 2016).

<b>GROUP 1: INJURIES STRONGLY ASSOCIATED WITH HIV INFECTION</b>	<b>GROUP 2: LESS COMMON INJURIES ASSOCIATED WITH HIV INFECTION</b>	<b>GROUP 3: INJURIES SEEN IN HIV INFECTION</b>
Erythematous; pseudomembranous candidiasis; angular cheilitis; Hairy leukoplast; Kaposi's Sarcoma; Non-Hodgkin's Lymphoma Periodontal disease: linear gingival erythema, necrotizing gingivitis, necrotizing periodontitis	Bacterial infections Mycobacterium avium intracellulare, Mycobacterium tuberculosis; Melanin hyperpigmentation; Necrotizing ulcerative stomatitis; Salivary gland disease: dry mouth, unilateral or bilateral enlargement of the major salivary glands;	Bacterial infections: Actinomyces israelii, Escherichia coli, Klebsiella pneumoniae; Cat Scratch Disease (Bartonella henselae); Epithelioid (bacillary) angiomatosis (Bartonella henselae); Drug reactions: ulcerations, erythema multiforme,

Thrombocytopenic purpura; Nonspecific ulcers; Viral infections herpes simplex human papillomavirus, chickenpox zoster.		lichenoid reactions, toxic epidermolysis; Fungal infections except candidiasis: Cryptococci neoformans, Geotrichum candidum, Histoplasma capsulatum, Mucoraceae (mucormycosis/zygomycosis) Aspergillus flavus Neurological disorders: facial palsy, trigeminal neuralgia; Recurrent aphthous stomatitis Viral infections: cytomegalovirus, molluscum contagiosum
--	--	--

## II. CANDIDIASIS

Candidiasis is an infection of fungal origin, whose etiologic agent of greatest incidence is *Candida albicans*. This microorganism lives in the oral mucosa of most individuals, waiting for an opportunity to present its pathogenicity (MARCUCCI et al., 2005). The presence of candidiasis in a patient affected by HIV by itself does not indicate progression to AIDS, but often leads to the initial diagnosis of HIV infection (NEVILLE, 2016). According to a study by Paulique et al. (2017), candidiasis can be found in four clinical patterns: pseudomembranous candidiasis, erythematous candidiasis, angular cheilitis and hyperplastic candidiasis. And this pathology is commonly found in patients with HIV/AIDS, resulting from depression of the immune system. Pseudomembranous candidiasis has a white or yellowish surface that can be removed through the semiotechnical scraping maneuver (PAULIQUE et al., 2017). When the pseudomembranous aspect occurs, the CD4+ lymphocyte count is often below 200 cells/mm<sup>3</sup> (NEVILLE, et al., 2016).

In the erythematous form, the lesion is reddish with a burning sensation in the middle posterior dorsum of the tongue, soft palate and mucous membranes (GOMES; SOARES; FELIPE, 2020). And this starts when the CD4+

lymphocyte count drops to less than 400 cells/mm<sup>3</sup> (NEVILLE, 2016).

As highlighted by Gomes, Soares and Felipe (2020), it is known that angular cheilitis is usually associated with the use of prostheses. This lesion causes pain resulting from the formation of cracks in the labial commissure, due to the junction of bacteria and fungi (*Staphylococcus aureus* and *Candida albicans*). The immunocompromised patient is susceptible to the involvement of angular cheilitis due to low immunity, poor oral hygiene, loss of vertical dimension and nutritional deficiencies.

The hyperplastic form has a hard and rough appearance on palpation, with a whitish color. It occurs mainly in the retrocommissural mucosa and is not removed by scraping, unlike pseudomembranous candidiasis (NASCIMENTO et al., 2020).

HIV infection, as highlighted by Pires et al. (2017), is often associated with psychiatric disorders, the most common being depression and tricyclic antidepressants (nortriptyline, amitriptyline) are used to treat it, but they have low flow as a side effect. salivary. And these medications can make the mucosa more susceptible to the appearance of candidiasis due to a common side effect of these medications, which is xerostomia.

The diagnosis is made through the clinical aspects of the lesion, which can also use exfoliative cytology with PAS or Grocott staining, and sometimes it is necessary to use a biopsy to rule out the possibility of other lesions (ALMEIDA, 2016). Treatment is through topical and systemic antifungal agents. Nystatin (100,000UI/ml) can be used as an oral suspension, nystatin in tablets, oral gel base such as 1% clotrimazole and miconazole. Furthermore, when the patient does not respond to topical therapy, systemic azoles such as fluconazole (150mg) and itraconazole (100mg) can be used (GOMES; SOARES; FELIPE, 2020).

It is noteworthy that individuals who have harmful habits, poor oral hygiene, wear removable dentures and have reduced salivary flow tend to have greater resistance to the usual therapies and this fact can lead to the evolution of oral candidiasis to the pharynx, esophagus and trachea (GOMES; SOARES; FELIPE, 2020).

According to Izoton and Israel (2020), topical and systemic therapies have some limitations and adverse effects that lead to resistance of these microorganisms, leading to an increase in relapses in a short period of time. Therefore, photodynamic therapy (PDT) has been studied and proved to be effective in the treatment of candidiasis in people living with HIV/AIDS. PDT consists of associating a light source and a photosensitizing dye

compatible with this light, applying them to tissue that has oxygen, thus promoting the death by photo-oxidation of pathogenic agents.

### III. ORAL LEUKOPLAKIA

Oral hairy leukoplakia is an opportunistic infection associated with the Epstein-Barr virus (EBV) and clinically presents as a white mucosal plaque that does not show a scaling. According to Gomes, Soares and Felipe (2020), it usually affects the lateral edge of the tongue with clinical features that can range from white, faint streaks to thick, corrugated leucoplastic areas, with a rough cerotic surface. However, these aspects are not pathognomonic. Rarely, the buccal mucosa, soft palate, esophagus and pharynx are affected (NEVILLE, 2016).

As reported by Paulique et al. (2017), its clinical appearance is often enough to make the diagnosis, but even so, cytopathology, histopathology, immunohistochemistry, in situ hybridization, PCR, and electron microscopy can be used. The treatment of OLP is often not necessary, although discomfort in the region and aesthetic needs may require therapy (NEVILLE, 2016). Therefore, it can be treated through cryotherapy or surgery, and anti-herpes virus drugs such as acyclovir and desiclovir generate rapid resolution.

Gomes, Soares and Felipe (2020) highlight that oral manifestation is considered a predictor of progression to AIDS and the identification of oral hairy leukoplakia in immunocompetent patients requires dentists to investigate the patient's serological status.

### IV. KAPOSI SARCOMA

KS is a multifocal neoplasm that originates from vascular endothelial cells. It manifests clinically with multiple lesions in the skin and oral cavity, although a single lesion is identified first. Commonly affected areas of the skin are the arms, trunk, head and neck. In the oral cavity, the most affected structures are the hard palate, gums and tongue, however, any region can be affected (NEVILLE, 2016).

They are clinically characterized as red or purple plaques, focal or diffuse, may be completely asymptomatic and may go unnoticed by professionals. They can even affect simple activities such as speaking and eating. In addition, they can lead to tooth loss and airway compromise (PAULIQUE et al., 2017).

Human herpes virus type 8 appears to be the infectious agent responsible for its development. Diagnosis is made through incisional biopsy, with the possibility of

performing immunohistochemistry, PCR or in situ hybridization to identify HHV-8 (GOMES; SOARES; FELIPE, 2020).

Borges, Real and Schreiner (2019) clarify that there are several treatment modalities for KS. Existing treatments include radiotherapy, laser therapy, cryotherapy, vincristine injections or surgical excision. It is noteworthy that most of these treatments do not cure, but reduce the size and number of lesions.

For patients who do not use antiretroviral drugs, they should start as soon as they are aware of their serological status, since these drugs act to control the replication of the virus and consequently improve the immune system, increasing the survival of these individuals (BORGES ; REAL; SCHREINER, 2019).

## V. NON-HODGKIN LYMPHOMA

Lymphoma is a neoplastic change where its precursors are divided into Hodgkin's Lymphoma (LH) and Non-Hodgkin's Lymphoma (NHL), usually this manifestation occurs in lymph nodes, and can also be extranodal, when it happens in extranodal it is usually found in the stomach, glands salivary, skin, bone and rarely in the oral cavity (GOMES; PIAZZA; CASTELO, 2019).

Non-Hodgkin's lymphoma is a malignant neoplasm that originates in lymphoid tissue, most commonly from cells of the series of B lymphocytes that have been transformed, but extranodal lymphomas are also found (KUMAR; ABBAS; FAUSTO, 2010).

The lymphoid tissue plays a fundamental role in the recognition and processing of non-environmental antigens, such as: fungi, viruses and bacteria. The highest prevalence of this disease is in patients with immunological alterations (NEVILLE, 2016).

According to Neville (2016), Non-Hodgkin Lymphoma has two types of presentation: nodal and extranodal. Nodal lymphoma that has slow growth with painless bulging, where the lesion covers local lymph nodes, considered a low-grade lymphoma, but with disease progression.

The other form of presentation is extranodal lymphoma, which, when in the mouth, affects soft tissue, causing an increase in volume, without painful and diffuse symptoms. The most common region in the mouth is the gingiva, followed by the palate, maxilla, amygdala, parotid, tongue, lip, oral mucosa, Waldeyer's ring, paranasal sinuses, laryngeal tissues and bone structure (GOMES; PIAZZA; CASTELO, 2019).

Clinical signs of NHL in the mouth include toothache, numbness, tooth mobility, cervical lymphadenopathy, ulcerated masses or lesions, with nonspecific radiographic exams (GOMES; PIAZZA; CASTELO, 2019).

Gomes, Piazza and Castelo (2019) note that this diagnosis of NHL is difficult to make, as it can be confused with other pathological entities, such as dentoalveolar and periodontal abscess, among others. For an assertive diagnosis it is necessary to perform an incisional biopsy and anatomopathological and immunohistochemical tests.

When diagnosed in a low degree (nodal), some experts recommend "wait and observe", as the progression is slow, and even when treated with chemotherapy, the tumor has a high rate of recurrence (NEVILLE, 2016).

Knowing this, to make the proper treatment, several factors must be considered, such as: the patient's medical history, systemic condition, stage and degree of lymphoma, surgical treatment is not recommended in NHL cases (NEVILLE, 2016).

According to Gomes, Soares and Felipe (2020), for extranodal NHL, treatment must be done with chemotherapy associated with radiotherapy, and a regimen of cyclophosphamide, doxorubicin, adriamycin, vincristine and prednisone. For Petroianu et al. (2020), CHOP chemotherapy is the best long-term treatment to be used when the disease is already generalized.

It is worth mentioning that NHL has different etiologies, where the disease may be related to heredity, environmental, occupational, dietary, immunological, and HIV factors, and this relationship is still poorly established in the literature (PETROIANU et al., 2020).

## VI. LINEAR GINGIVAL ERYTHEMA

According to Neville (2016), linear gingival erythema is an oral manifestation strongly associated with HIV. Sometimes ELG is confused with conventional marginal gingivitis. The disease is believed to be an abnormality in the host's immune response to bacteria. However, it is known that this lesion is associated with other pathologies and is not restricted to PLHIV.

According to Dominguez Filho et al. (2021), linear gingival erythema is associated with the Acquired Immunodeficiency Virus. In a cross-sectional study with 100 HIV-positive patients, 6 of them had the pathology. Its characteristics in the bacterial origin are presented as a linear erythematous and edematous band, persistent and easily bleeding, and in the marginal gingiva a distance of 2

to 3 mm from the free gingiva, which may extend to the alveolar mucosa (BARROS et al., 2017).

Oral candidiasis and linear gingival erythema have been diagnosed together, assuming that *Candida* spp has a strong association as an etiologic agent. Monitoring with an interval of two to three months is essential to check whether the patient is developing more severe periodontal diseases, it is known that marginal gingivitis that responds easily to treatment are not ELG (BARROS et al., 2017).

Treatment consists of debridement of the lesion, irrigation with iodinated alcohol, chlorhexidine and antifungal agents (NEVILLE, 2016).

### VII. NECROTIZING ULCERATIVE PERIODONTITIS

Periodontal disease is one of the most common pathologies found in PLHIV patients, even those undergoing treatment. This lesion can often be found in the oral cavity before diagnosis, as several authors point out that this oral manifestation may be the first sign of the disease (BARROS et al., 2017).

According to Gomes, Soares and Felipe (2020), the main difference between Necrotizing Ulcerative Periodontitis (PUN) and Necrotizing Ulcerative Gingivitis (GUN) is the loss of periodontal attachment and bone, where periodontal pockets are hardly found, the exposure of tubercles Bone, ulcerated and necrotic lesions with spontaneous bleeding are similar to GUN.

The symptomatology of the disease is intense pain, edema, spontaneous hemorrhage, loss of more than 6 mm of attachment within a period of six months, periodontal pockets are rarely found due to the progression of necrosis in gingival tissue and adjacent alveolar bone loss (NEVILLE, 2016).

Periodontal disease can act as an operant for the reactivation of HIV as it can be linked to systemic changes, so the treatment is extremely important so that there is no immunosuppression due to an opportunistic infection, the protocol used does not differ from the patients who do not have HIV (BARROS et al., 2017).

Control of bacterial plaque, probing periodontal pockets, debridement of necrotic tissue, pain control, antimicrobial treatment and use of metranidazole as immediate treatment for a prolonged period. Initially, mouthwashes with chlorhexidine should be done, after the initial debridement, the removal of other compromised tissues follows, where the interval should be 24 hours and repeated every 10 days in two or three consultations,

depending on the patient's systemic response (PAULIQUE et al., 2017).

It is recommended that, starting from this first improvement, the consultation with the patient should be monthly, and observing how the pathology is progressing, these visits extend to three months (NEVILLE, 2016).

### VIII. NECROTIZING ULCERATIVE GINGIVITES

According to Sartori et al. (2019), 11% of the population living with HIV is affected by necrotizing ulcerative gingivitis, with young adults being the most affected. Paulique et al. (2017) point out that in the normal population the index is less than 0.1%.

Necrotizing ulcerative gingivitis is an infection by gram-negative bacteria such as spirochetes, spindle bacteria and *Prevotella intermedia* that cause inflammation in the region of free gingiva, attached gingiva and vestibular and jugmental mucosa (NEVILLE, 2016; PAULIQUE et al., 2017 ; SARTORI et al., 2019).

Patients with GUN have profuse and spontaneous bleeding, severe edema, necrotic lesions, painful symptoms, foul odor and no loss of periodontal attachment (NEVILLE, 2016; PAULIQUE et al., 2017).

As a treatment plan in more acute cases of the disease, the debridement of lesions and root and coronary planing are formulated (SARTORI et al., 2019) with hydrogen peroxide irrigation (NEVILLE, 2016), as the main colonies of micro-organisms are gram-negative and are close to the external gingiva region (PAULIQUE et al., 2017), the use of gauze soaked in 0.12% corhexidine is necessary for the removal of necrotic tissue associated with chlorhexidine mouthrinse GOMES; SOARES; FELIPE, 2020), make a prescription with the use of antibiotics, after the first clinical sequence, follow-up is followed every 1 month, with a satisfactory immune response, extend the visits to every 3 months.

### IX. DISCUSSION

The HIV virus is a retrovirus that infects CD4+ T cells, causing depression of the immune system and making it vulnerable to the involvement of opportunistic infections and neoplasms of different etiologies (BORGES; REAL; SCHREINER, 2019).

According to Quaresma et al. (2019), the individual can develop the most advanced stage of the disease, which

is AIDS, and this can take many years. The author emphasizes that the means of HIV transmission are: unprotected sex, contaminated blood transfusion, occupational accidents, through mother to child during the perinatal period and breastfeeding.

Neville (2016) argues that oral manifestations are among the first symptoms of HIV infection, where its progression alerts to the most acute phase of the disease, AIDS. Aitken-Saavedra et al. (2021) support that it is one of the first appearances associated with the disease and emphasizes the importance of the dentist in early diagnosis.

The classification of oral manifestations shows that candidiasis is a lesion with the highest rate in patients infected by the pathology (MARCUCCI, 2005), not being a marker of disease progression (NEVILLE, 2016), but being an indicative lesion for initial diagnosis, it can affect up to 94% of patients (AITKEN-SAAVEDRA et al., 2021). As described by Izoton and Israel (2020), candidiasis can be treated through topical and systemic therapies, however, these methods have some limitations and can be associated with photodynamic therapy (PDT).

Pizzolato et al. (2018) point out that oral manifestations can be bacterial, viral, fungal, neoplastic and of idiopathic etiology. Its most common manifestations are Candidiasis (pseudomembranous, erythematous, angular and hyperplastic cheilitis), Hairy Leukoplakia, Kaposi's Sarcoma, Non-Hodgkin Lymphoma and presentations of periodontal diseases, which is one of the lesions often associated with HIV, manifestations such as linear erythema gingival, GUN and PUN mark the progression (NEVILLE, 2016) without the effectiveness of HAART (GOMES; SOARES; FELIPE, 2020), where periodontal disease can be an operant for the reactivation of HIV and contribute to the progression to AIDS (AITKEN -SAAVEDRA et al., 2021).

HIV is still a public health problem and still has no cure. However, Highly Active Antiretroviral Therapy (HAART) enables the increase of TCD4+ lymphocytes, reducing the appearance of lesions in the oral cavity (ARAÚJO-JÚNIOR et al., 2018). However, Paulique et al. (2017) report that even with current treatments, the susceptibility to oral lesions is still high in these patients. However, the dentist must be able to diagnose and treat these injuries early.

## X. CONCLUSION

The present work shows which are the most frequent lesions in patients infected with the HIV virus and that even when undergoing therapy, these individuals may

be more susceptible to opportunistic infections due to depression of the immune system. It is observed that the appearance of these lesions function as a clinical marker of new virus infections, therapeutic failure or disease progression. Given the above, the dentist has a fundamental role in the recognition of these pathologies and must be able to carry out an early diagnosis, which may indicate the first symptoms of the disease and assist in treatment, promoting quality of life for people affected by the HIV virus.

## REFERENCES

- [1] Paulique, n. c. et al. manifestações bucais de pacientes soropositivos para hiv/aids. **arch. health invest.**, v. 6, n. 6, p. 240-244, 2017. disponível em: <<http://dx.doi.org/10.21270/archi.v6i6.2067>>. acesso em: 21 ago. 2021.
- [2] Nascimento, c. f. do et al. desmistificando o atendimento odontológico para paciente soropositivo: revisão de literatura. **braz. j. of develop.**, v. 6, n. 11, p. 91634-91652, 2020. disponível em: <<https://www.brazilianjournals.com/index.php/brjd/article/view/20425>>. acesso em: 28 ago. 2021.
- [3] Barros, a. v. m. de et al. doenças periodontais em pacientes hiv positivos: uma revisão da literatura. **revista periodontia**, v. 27, n. 2, p. 54-60, 2017. disponível em: <<https://pesquisa.bvsalud.org/portal/resource/pt/biblio-847103>>. acesso em: 10 set. 2021.
- [4] Neville, b. **patologia oral e maxilofacial**. rio de janeiro: elsevier, 2016.
- [5] Brito, m. a. de. fármacos recentes usados para o tratamento da infecção pelo hiv-1: enfuvirtida, maraviroc, raltegravir e etravirina. **rev. ciênc. farm. básica apl.**, v. 32, n. 2, p. 159-168, 2011. disponível em: <<https://rcfba.fcfar.unesp.br/index.php/ojs/article/view/340>>. acesso em: 21 ago. 2021.
- [6] Dominguez filho, o. de j. l. et al. manifestações orais em pacientes imunodeprimidos pelo vírus da imunodeficiência humana (hiv): revisão da literatura. **revista eletrônica acervo saúde**, v. 13, n. 2, p. 1-7, 2021. disponível em: <<https://doi.org/10.25248/reas.e6034.2021>>. acesso em: 21 ago. 2021.
- [7] Quaresma, m. do s. m. et al. prevalência de doenças oportunistas em pacientes hiv positivos em uma unidade de referência da amazônia. **revista eletrônica acervo saúde**, v. 11, n. 5, p. 1-9, 2019. disponível em: <<https://doi.org/10.25248/reas.e306.2019>>. acesso em: 21 ago. 2021.
- [8] Araújo-júnior, j. l. de et al. perfil clínico e epidemiológico das alterações bucais em portadores do hiv. **arch. health invest.**, v. 7, n. 8, p. 339-343, 2018. disponível em: <<http://dx.doi.org/10.21270/archi.v7i8.3022>>. acesso em: 21 ago. 2021.
- [9] Gomes, m. a. b.; soares, m. v. s.; felipe, l. c. da s. manifestações orais e tratamento em pacientes decorrentes da síndrome imunodeficiência adquirida: revisão de literatura. **facit business and technology journal**, v. 1, n. 21, p. 88-104, 2020. disponível em: <<http://revistas.faculdadefacit.edu.br/index.php/jnt/article/view/770>>. acesso em: 28 ago. 2021.

- [10] Pires, a. b. et al. reações adversas na cavidade oral em decorrência do uso de medicamentos. **rev. salusvita**, v. 36, n. 1, p. 157-185, 2017. disponível em: <[https://secure.unisagrado.edu.br/static/biblioteca/salusvita/salusvita\\_v36\\_n1\\_2017\\_art\\_12.pdf](https://secure.unisagrado.edu.br/static/biblioteca/salusvita/salusvita_v36_n1_2017_art_12.pdf)>. acesso em: 28 ago. 2021.
- [11] Almeida, o. p. **patologia oral**. são paulo: artes médicas, 2016.
- [12] Izoton, c. f. g.; israel, m. s. eficácia antimicrobiana da terapia fotodinâmica no tratamento da candidíase oral em pessoas vivendo com hiv/aids. **rev. pesqui.(univ. fed. estado rio j. online)**, v. 12: p. 505-509, 2020. disponível em: <<https://doi.org/10.9789/2175-5361.rpcfo.v12.8598>>. acesso em: 10 set. 2021.
- [13] Borges, s. a. l.; real, l. h. g.; schreiner, r. b. sarcoma de kaposi em pacientes hiv: novamente uma realidade. **revista eletrônica acervo saúde**, v. 11, n. 6, p. 1-6, 2019. disponível em: <<https://doi.org/10.25248/reas.e352.2019>>. acesso em: 21 ago. 2021.
- [14] Gomes, r. f. t.; piazza, j. l.; castelo, e. f. linfoma não-hodgkin, manifestação no sistema estomatognático: relato de caso clínico. **revista saúde**, v. 45, n. 3, p. 1-7, 2019. disponível em: <<https://periodicos.ufsm.br/revistasaude/article/view/32478/0>>. acesso em: 28 ago. 2021.
- [15] Kumar, v.; abbas, a.; fausto, n. **robbins e cotran – patologia: bases patológicas das doenças**. rio de janeiro: elsevier, 2010.
- [16] Petroianu, a. et al. etiopathogenic, epidemiologic and clinical-therapeutic comparison of non-hodgkin's lymphoma and kaposi's sarcoma. **arq. bras. cir. dig.**, v. 33, n. 2, p. 1-4, 2020. disponível em: <<https://doi.org/10.1590/0102-672020200002e1521>>. acesso em: 10 set. 2021.
- [17] Sartori, l. r. m. et al. gengivite ulcerativa necrosante: um relato de caso. **revista da faculdade de odontologia de lins**, v. 29, n. 1, p. 39-46, 2019. disponível em: <<https://www.metodista.br/revistas/revistas-unimep/index.php/fo/article/download/4099/2322>>. acesso em: 21 ago. 2021.
- [18] Marcucci, g. et al. **fundamentos de odontologia: estomatologia**. rio de janeiro: guanabara koogan, 2005.
- [19] Aitken-saavedra, j. et al. oral lesions diagnosis associated with hiv: report of 3 clinical cases. **revista estomatológica hereditaria**, v. 31, n. 2, p. 140-147, 2021. disponível em: <<https://doi.org/10.20453/reh.v31i2.3975>>. acesso em: 21 ago. 2021.
- [20] Pizzolato, b. et al. oral manifestations in hiv patients. **j. interdiscipl. med. dent. sci.**, v. 6, n. 1, p. 1-4, 2018. disponível em: <10.4172/2376-032x.1000228>. acesso em: 10 set. 2021.